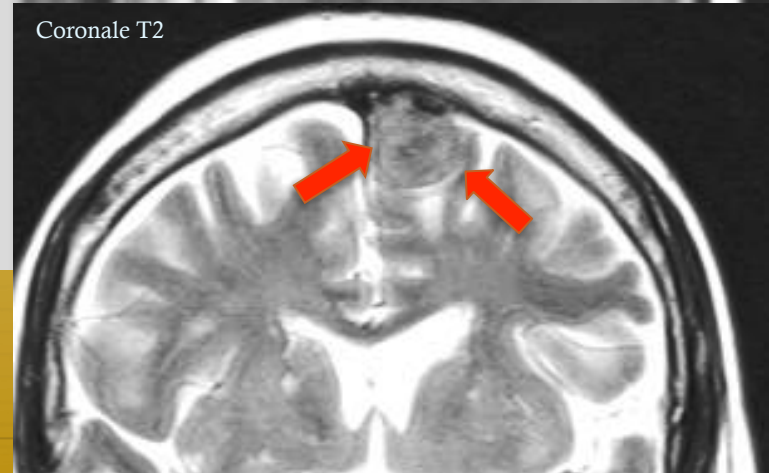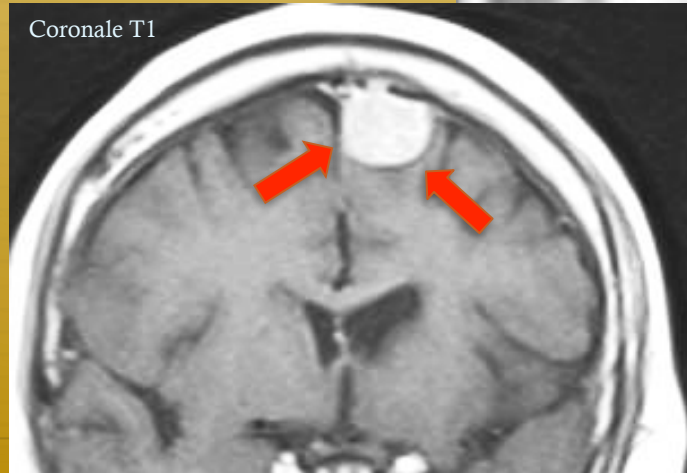
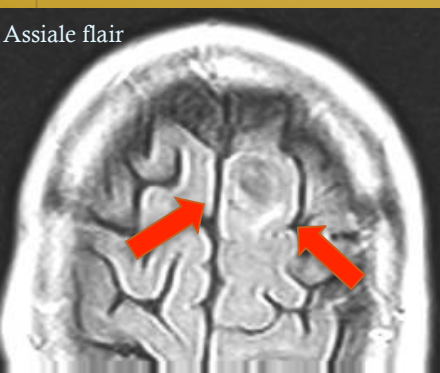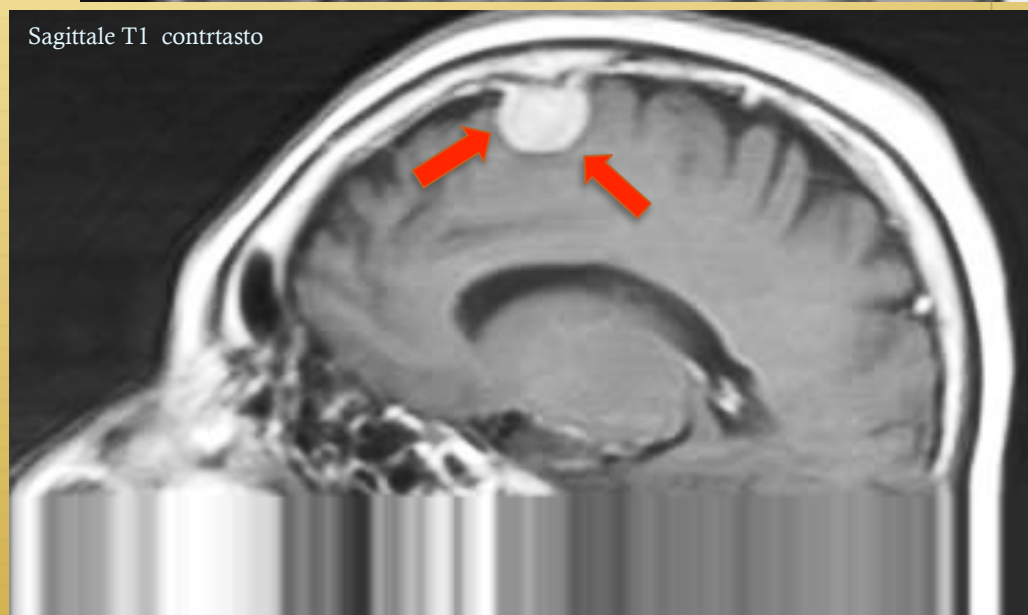
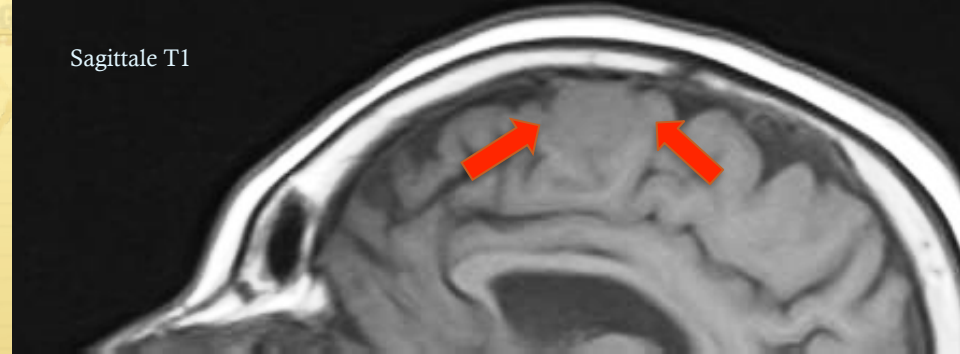
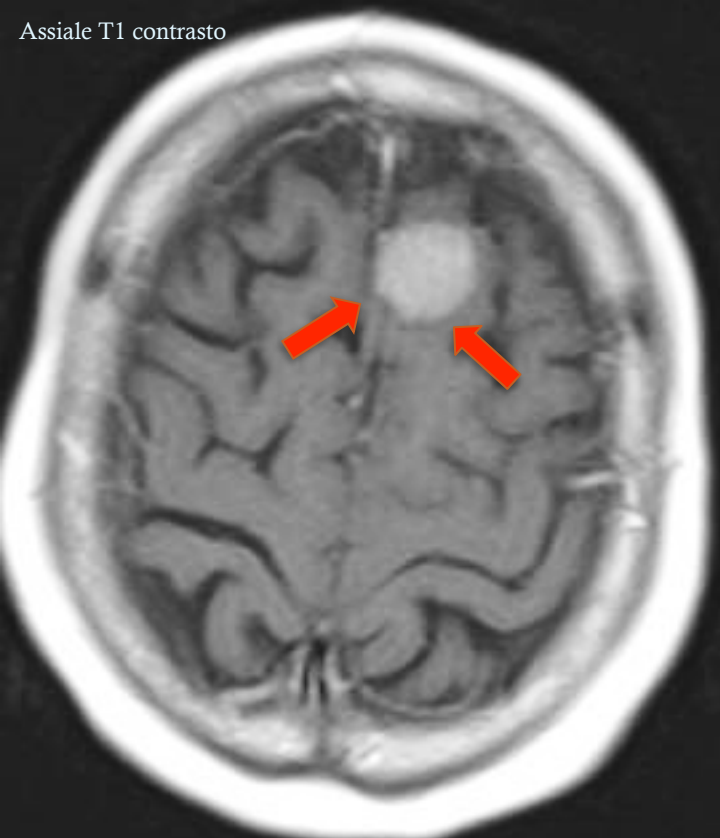
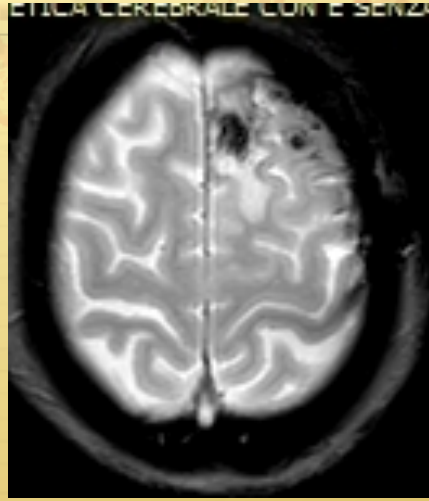
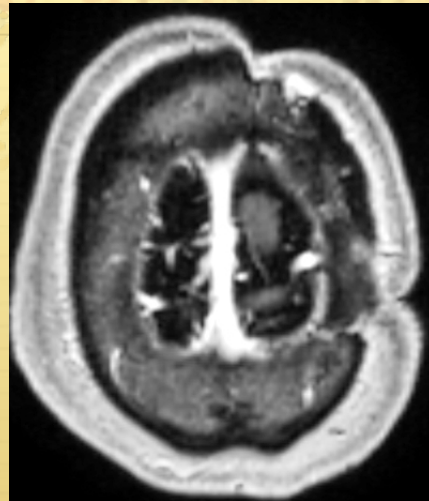
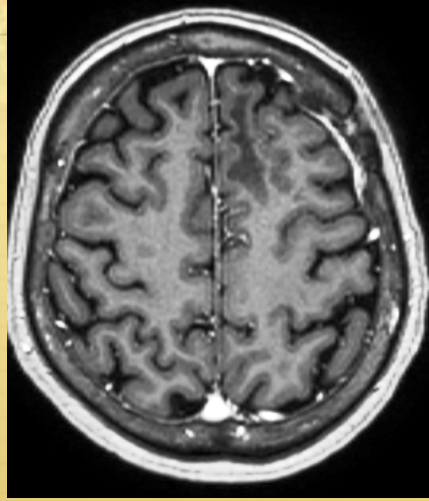
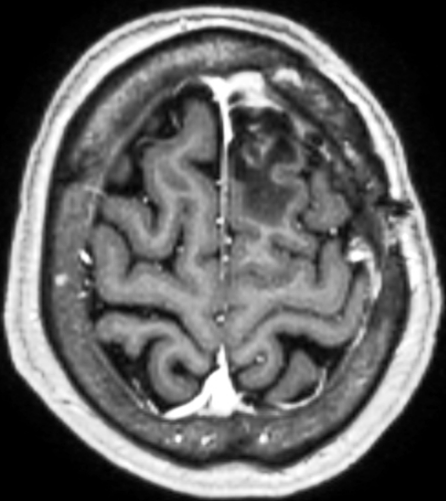




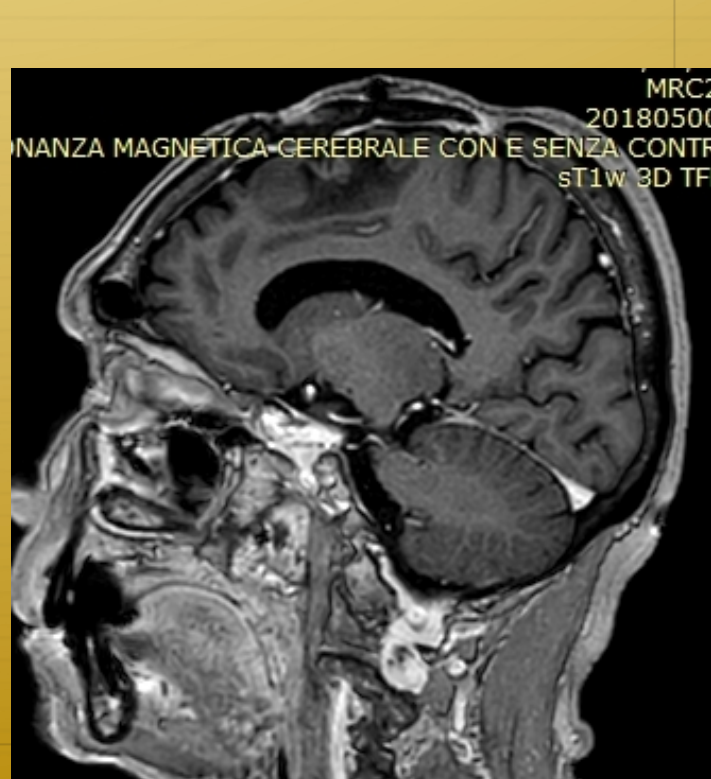
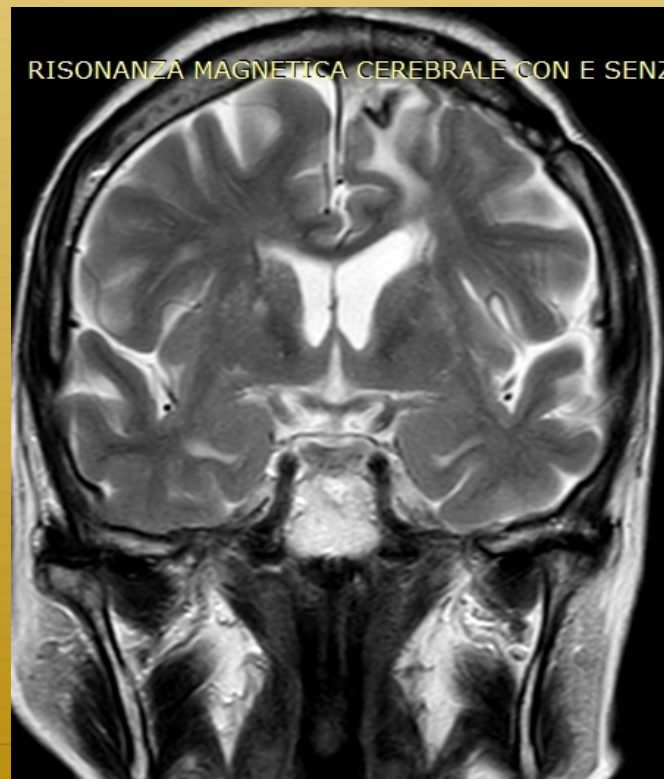
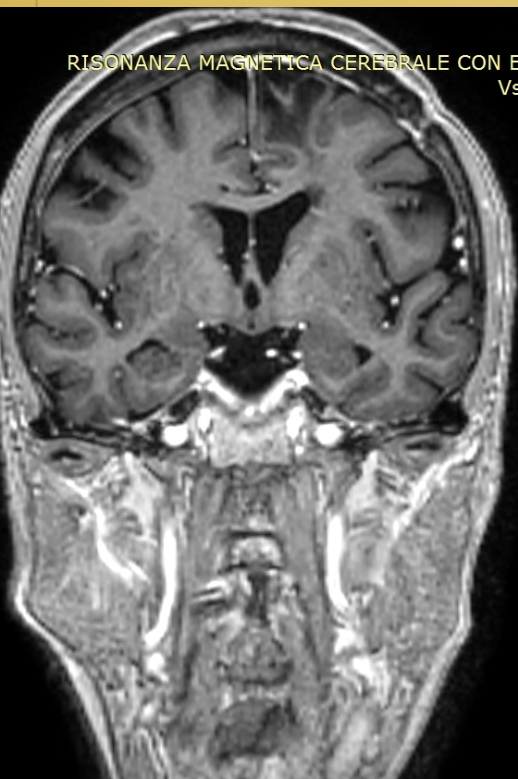
MENINGIOMA PAARASAGITTALE

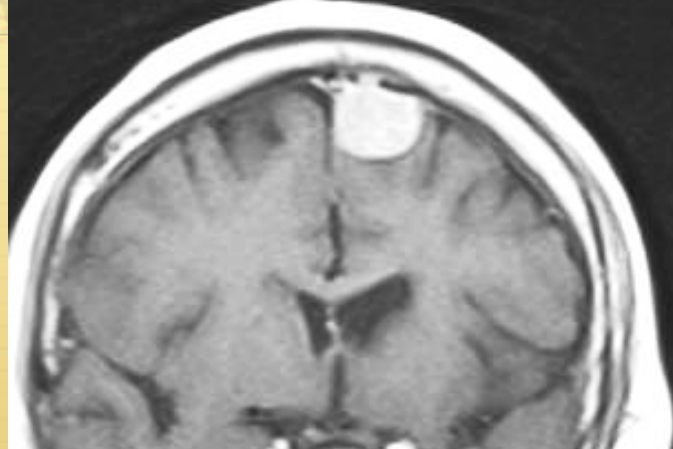
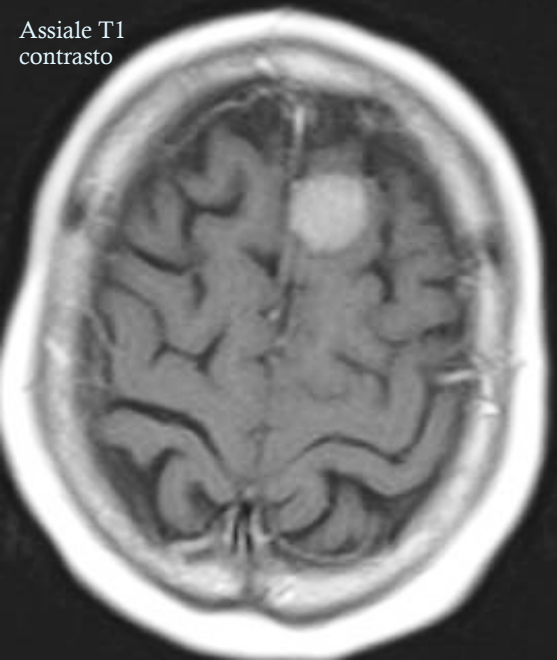
—◆—◆—
V.E.





Esiti dchirurgici con craniotomia frontale destra. Sportello osseo in buonaa posizione. Con area di malacia metachirurgica a contorni gliocicatrizziali cortico – sottocorticale. Non si rilevano immagini e/o aree di patologica impregnazione da rirefire a residuo/ recidiva della lesione asportata. Regolare morfologia delle restanti strutture encefaliche con rilievo di molteplici areole di gliosi su base vascolare nella sostanza bianca biemisferica disposte in sede paraventricolare





RMN preoperatoria
RMN postoperatoria

