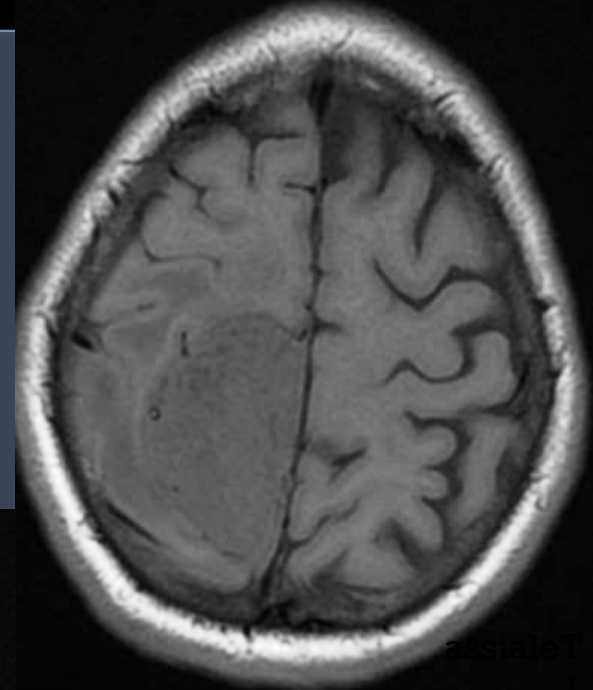
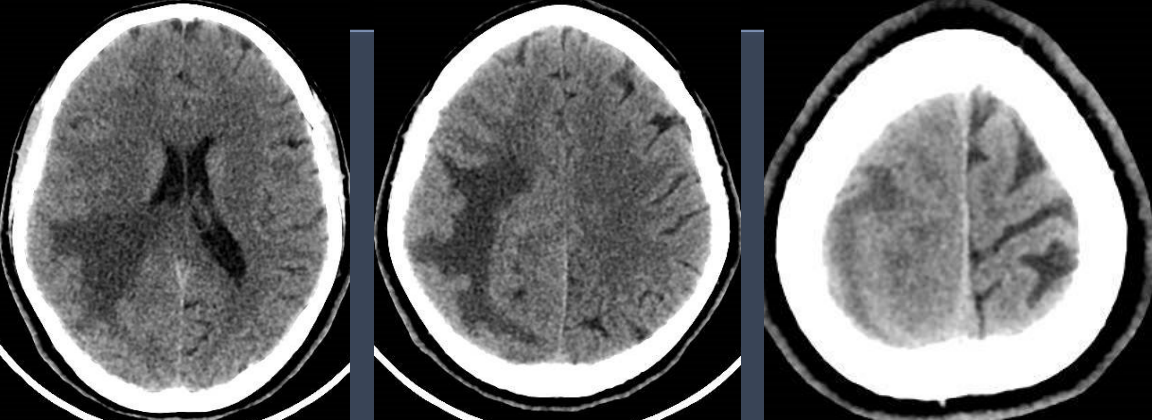
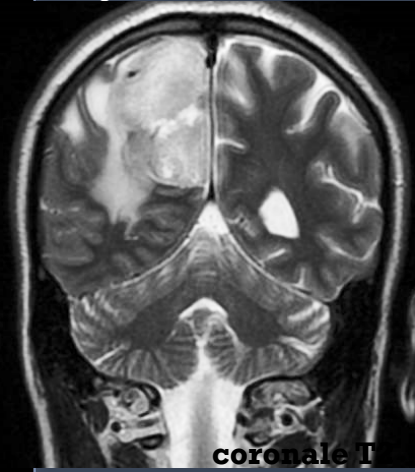


# Meningioma parasagittale terzo medio – terzo posteriore

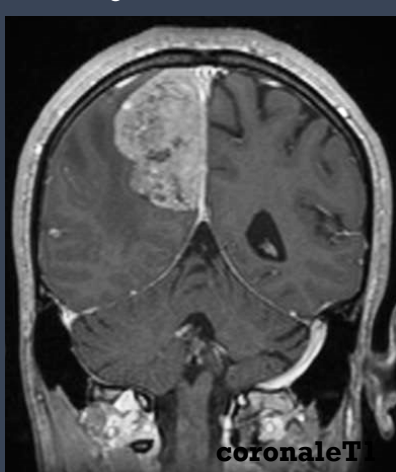
P. M.



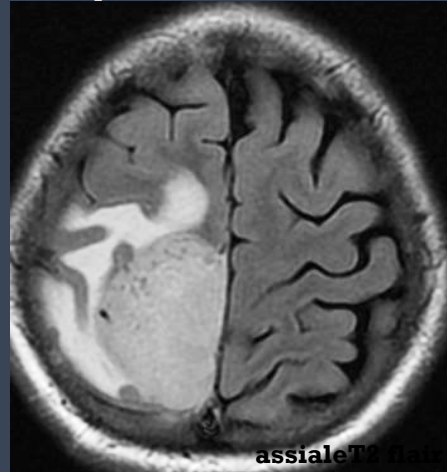
**TAC CEREBRALE** : Lesione espansiva frontoparietale parasagittale destra altamente edemigena, adesa alla falce . Fenomeni degenerativi cistici intralisionali. Compresso il



coronale T1

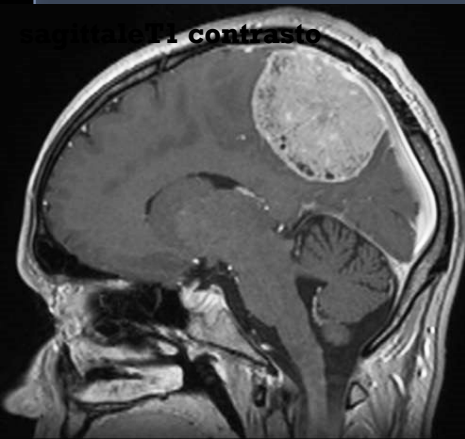


coronale T1  
contrasto



assiale T2 nat

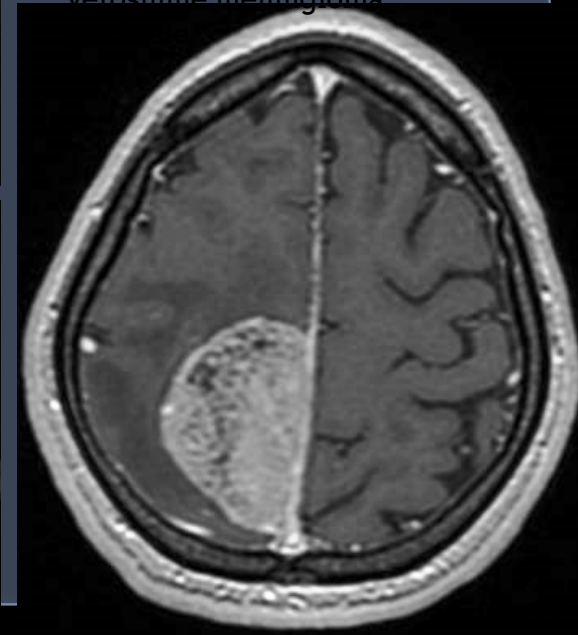
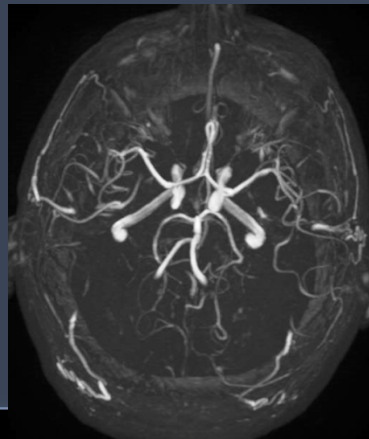
Evidenza di microcisti intralisionali. Verosimile meningioma

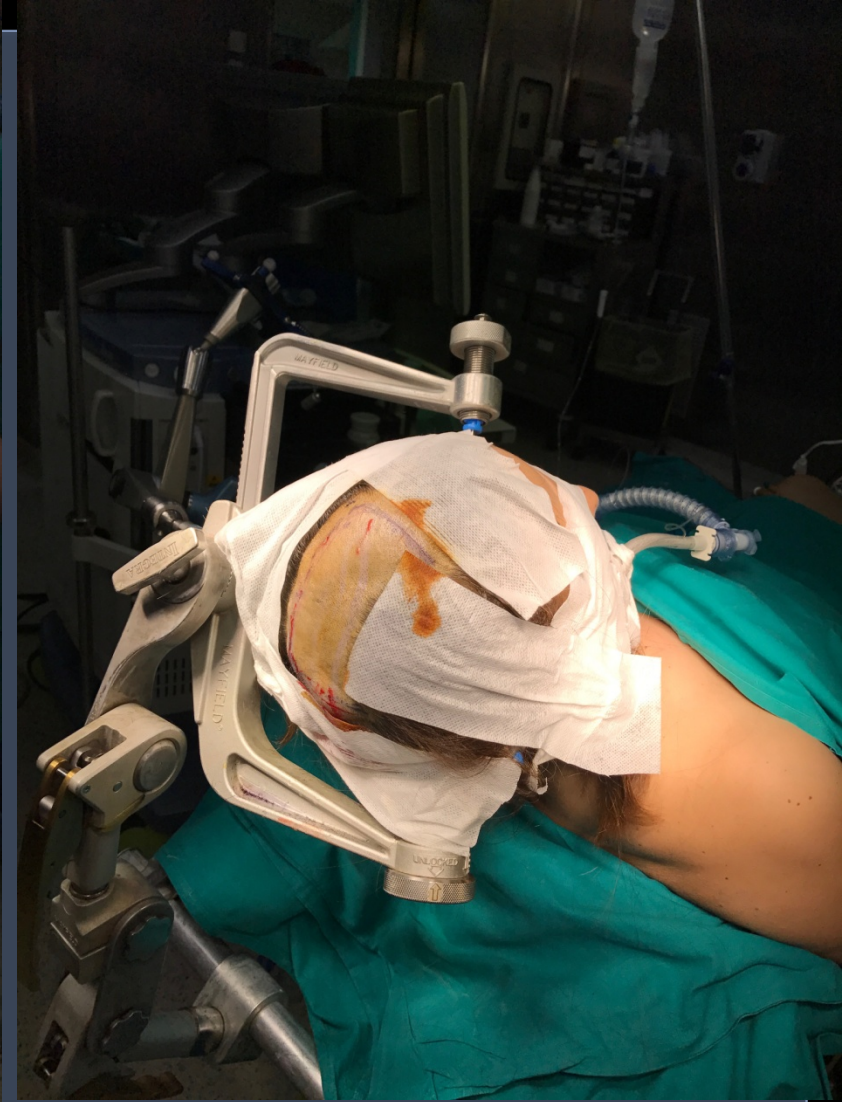
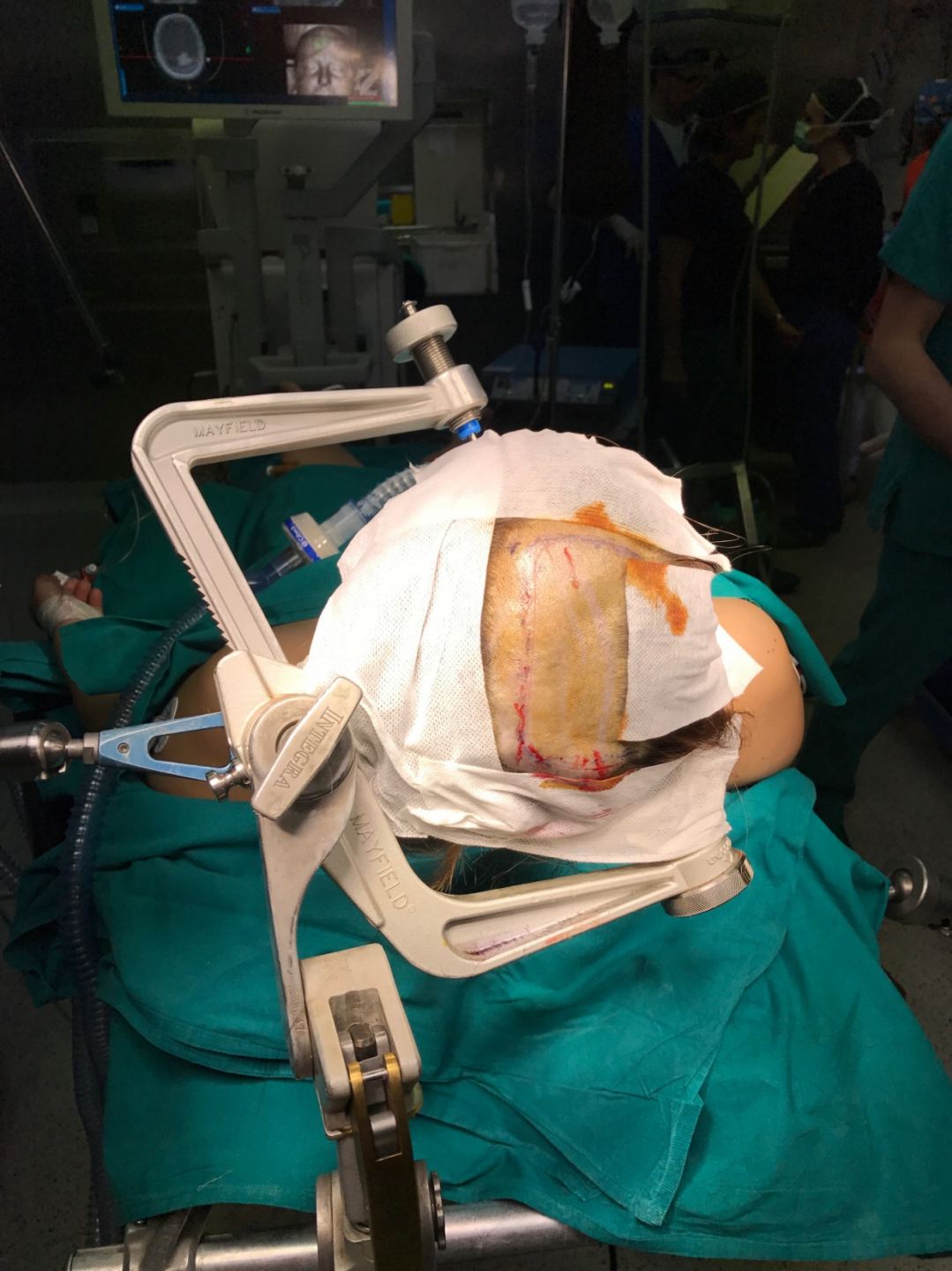
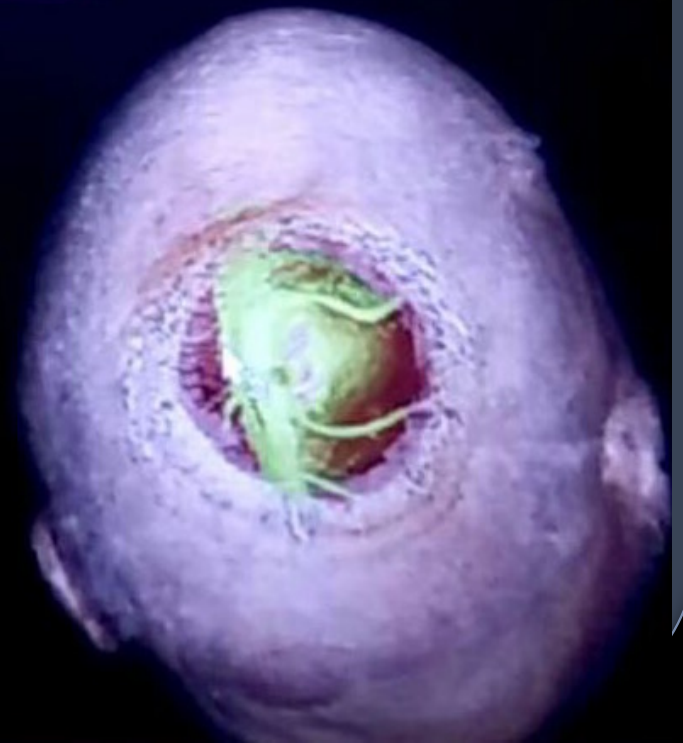
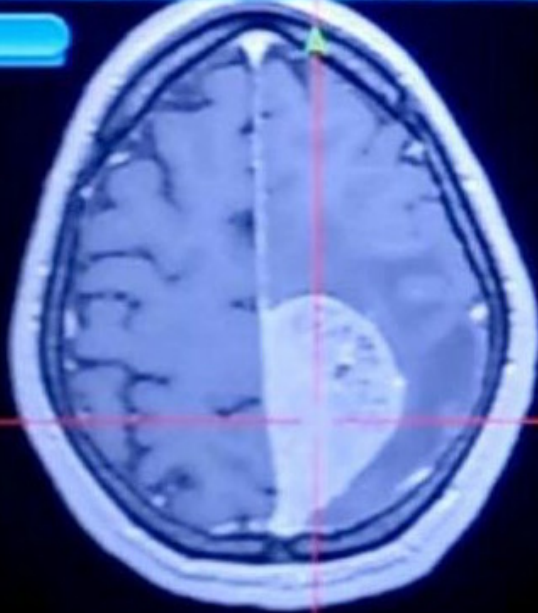
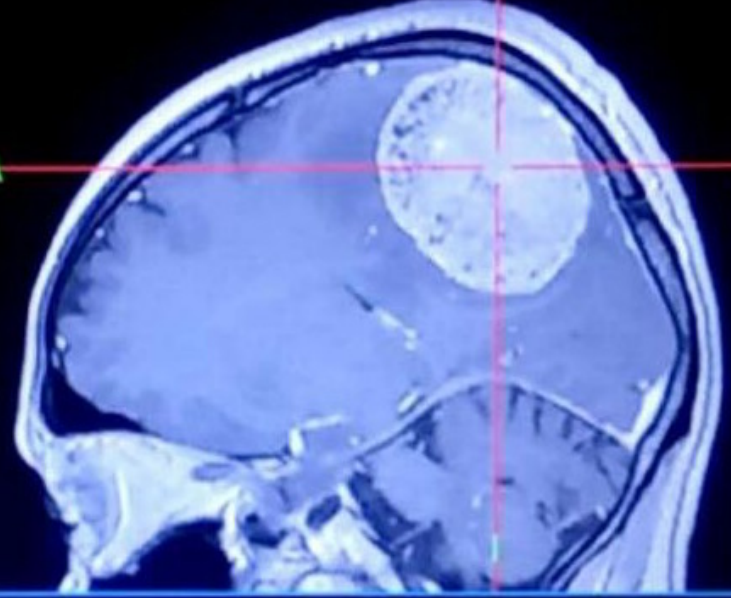
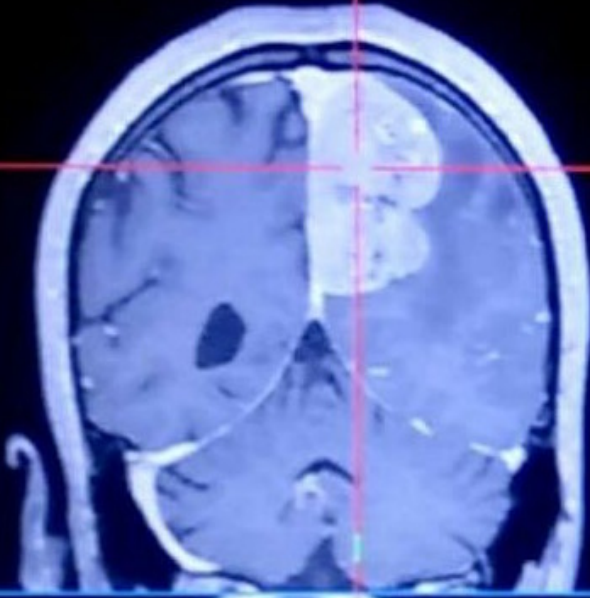
coronale T1  
contrasto

**RM ENCEFALO SENZA E CON CONTRASTO CON ANGIO-RM**

Processo espansivo extra-assiale adeso alla falce posteriore frontoparietale destro del diametro di 5 x 5 x 4 cm circa con notevole edema della sostanza bianca adiacente. Netta l'intensificazione del segnale della lesione dopo contrasto. Sebbene adiacente al seno longitudinale superiore non si apprezzano







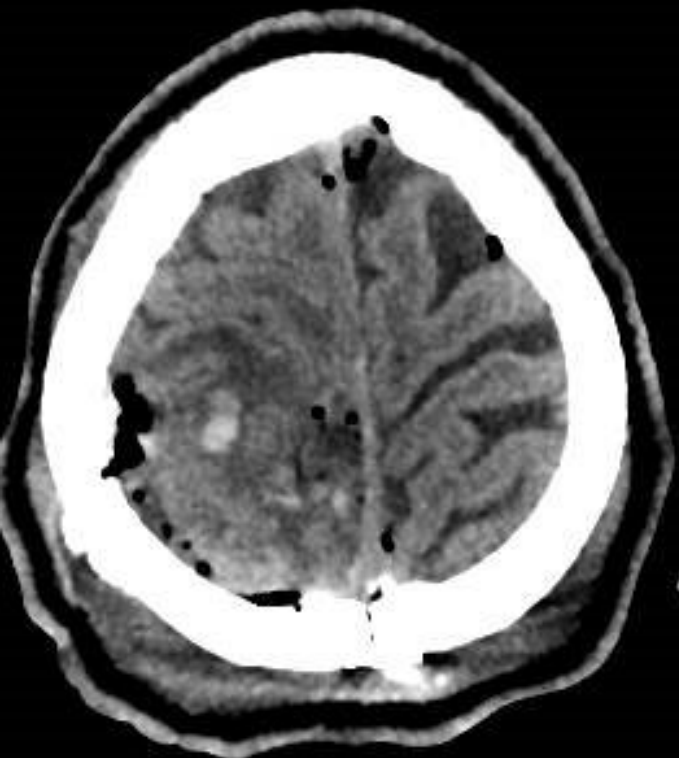
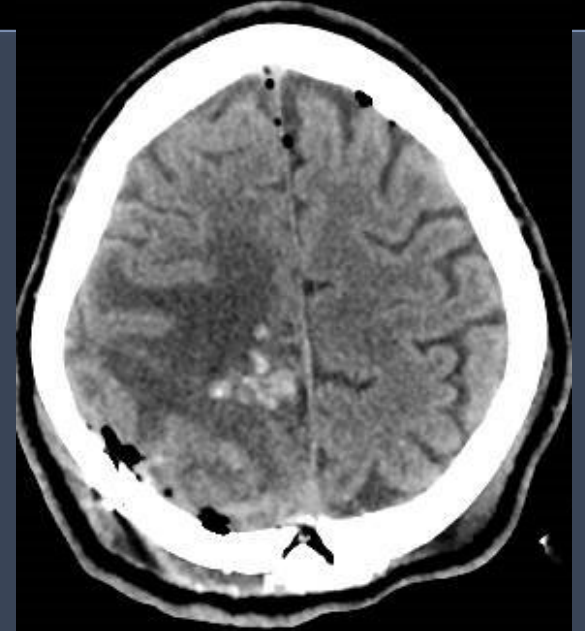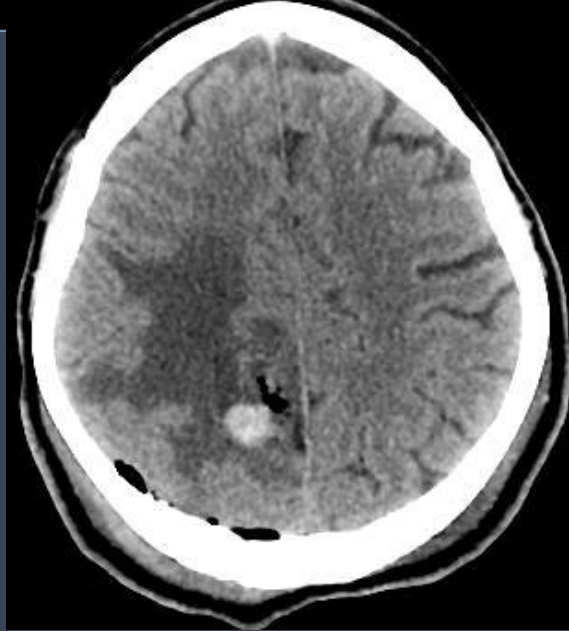
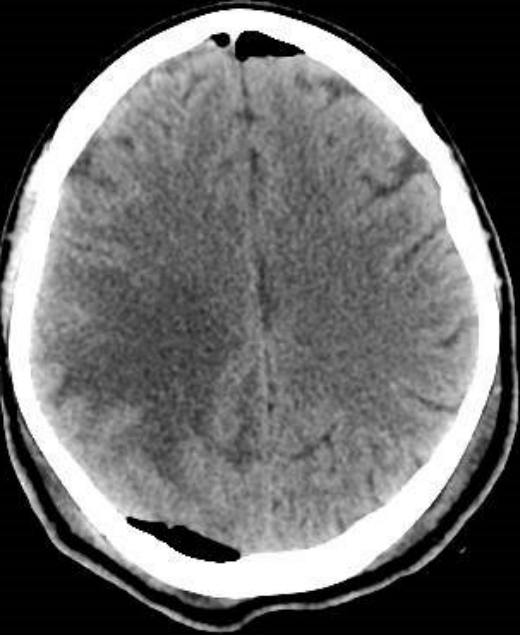
R

A

R

P

▶ 10



**TAC CEREBRALE**  
Controllo post-  
operatorio.

Asportazione  
completa della  
lesione.

Edema residuo.

Assenza di  
complicanze.

