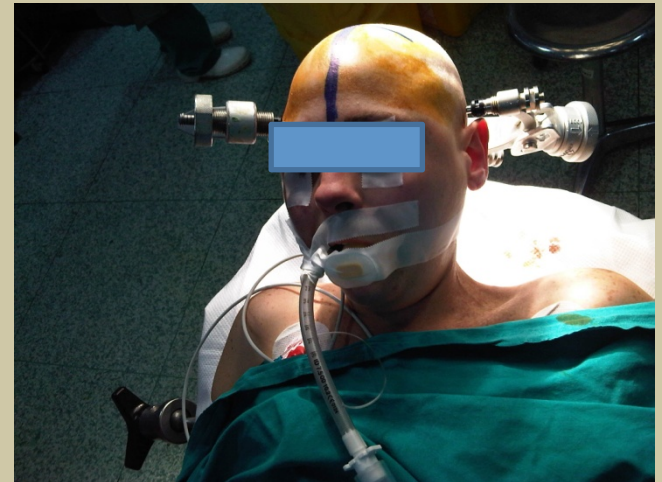
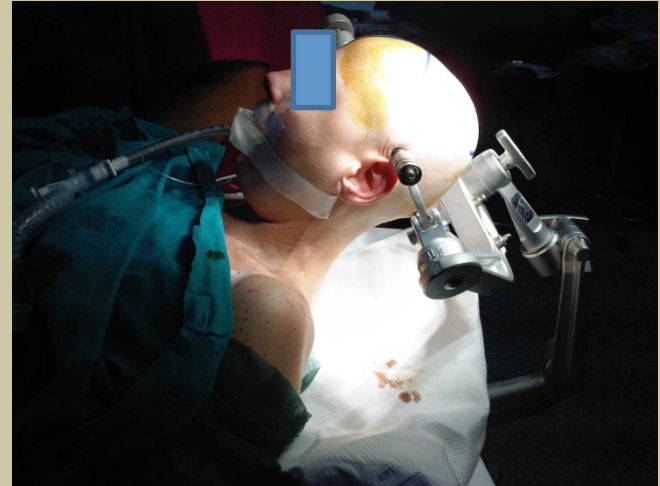
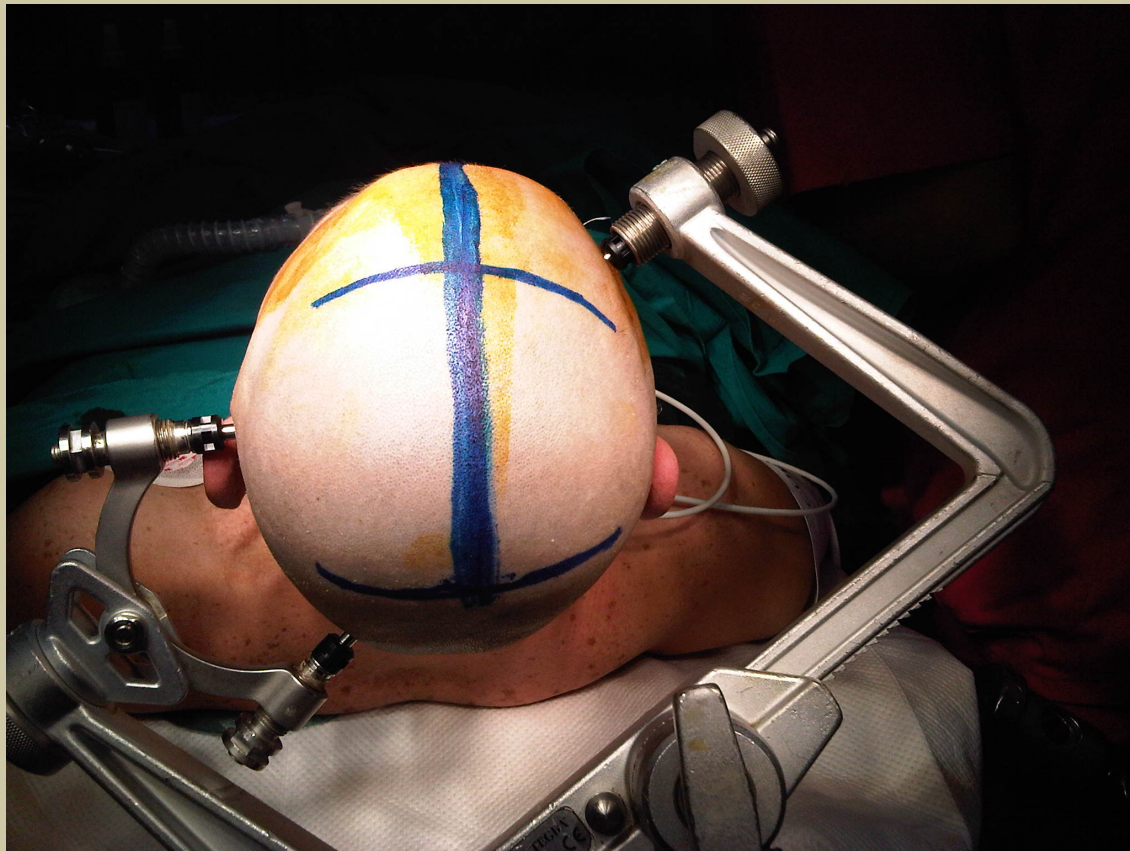


Meningioma della falce, 1/3 medio, a sviluppo bilaterale

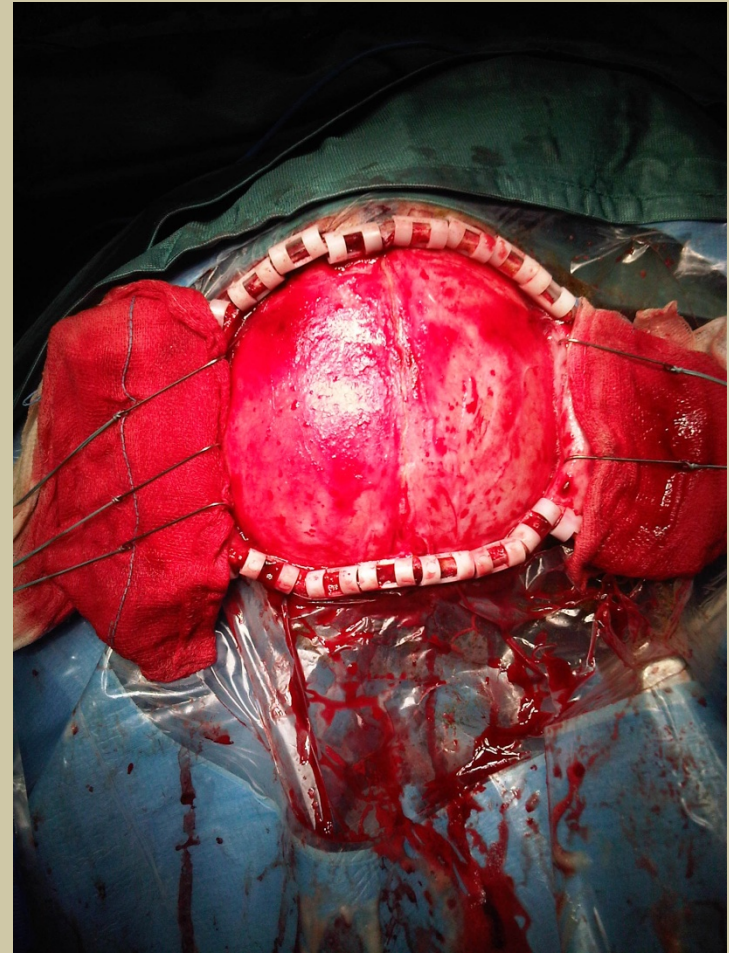
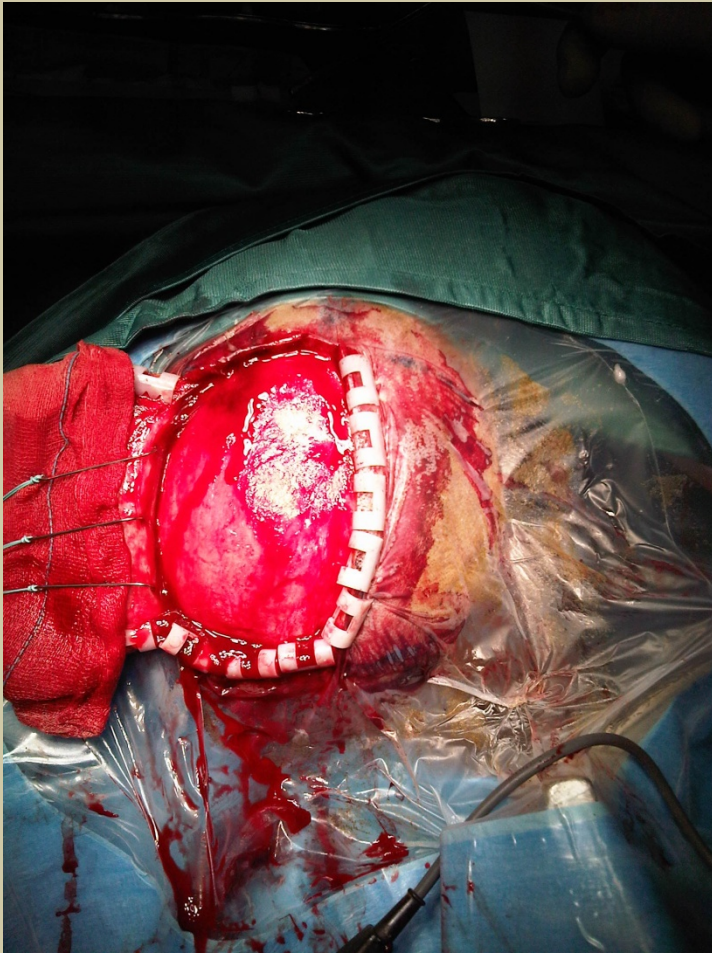D.P.F.

STEPS OPERATORI

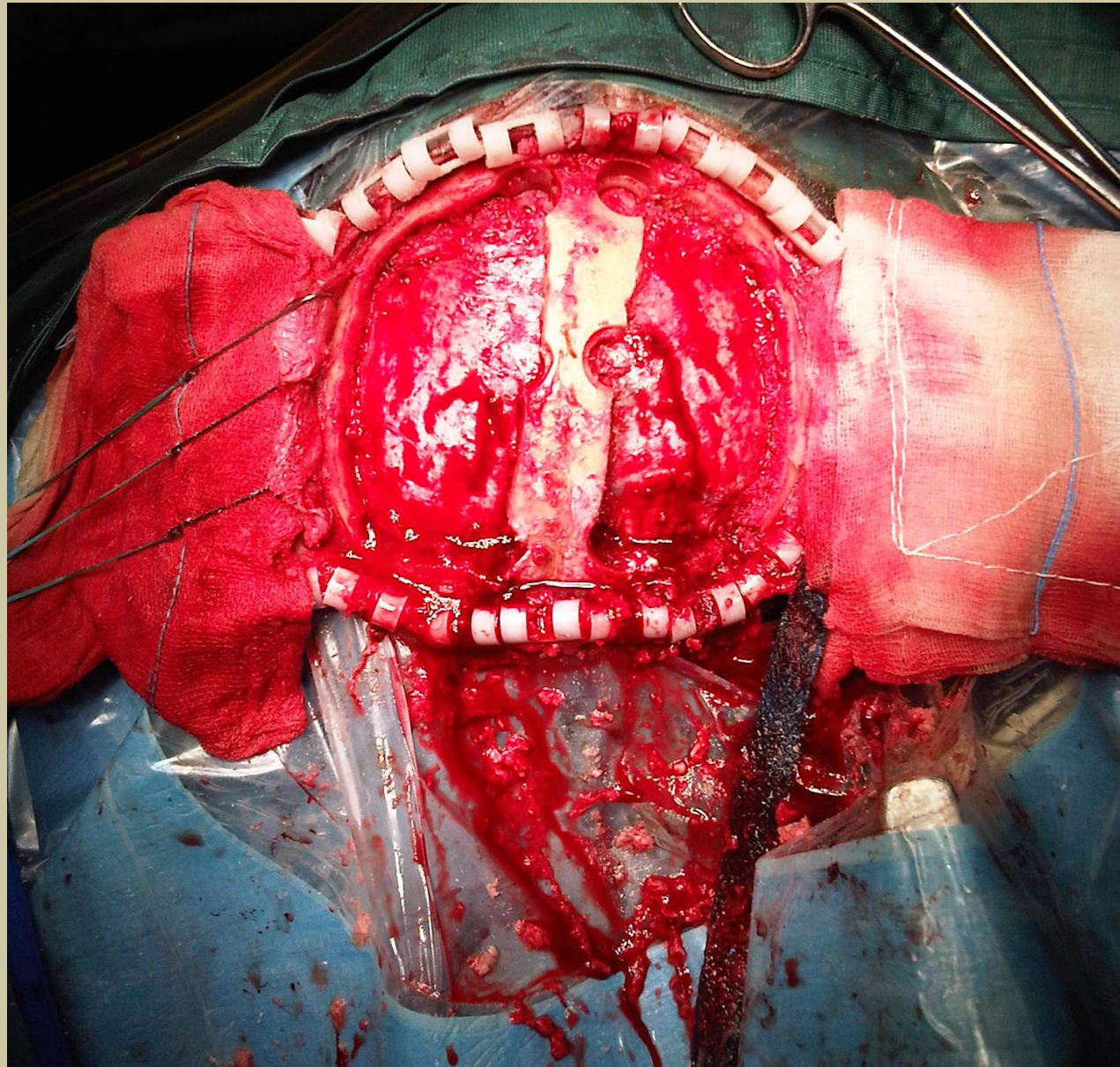
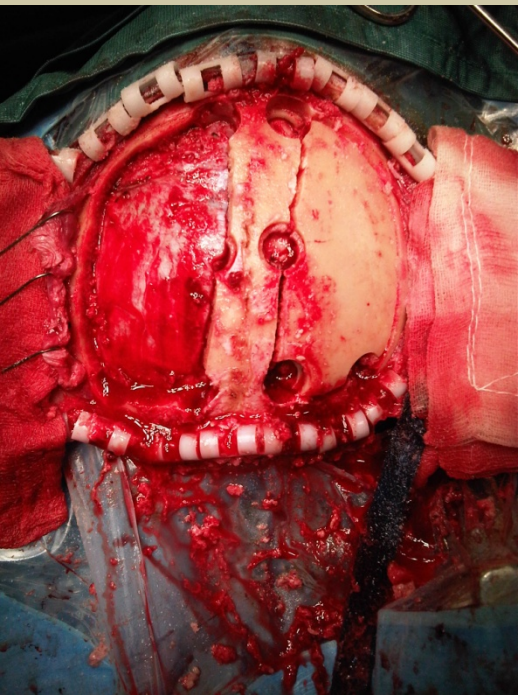
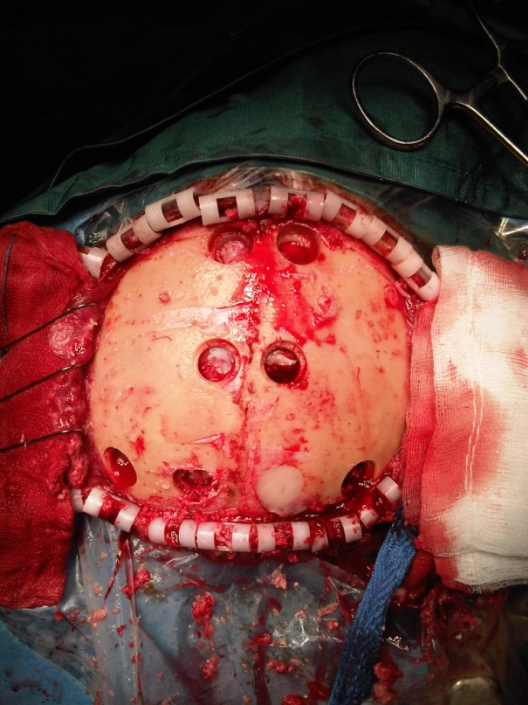
La paziente fu sottoposta ad exeresi della voluminosa neoplasia del terzo medio della falce.

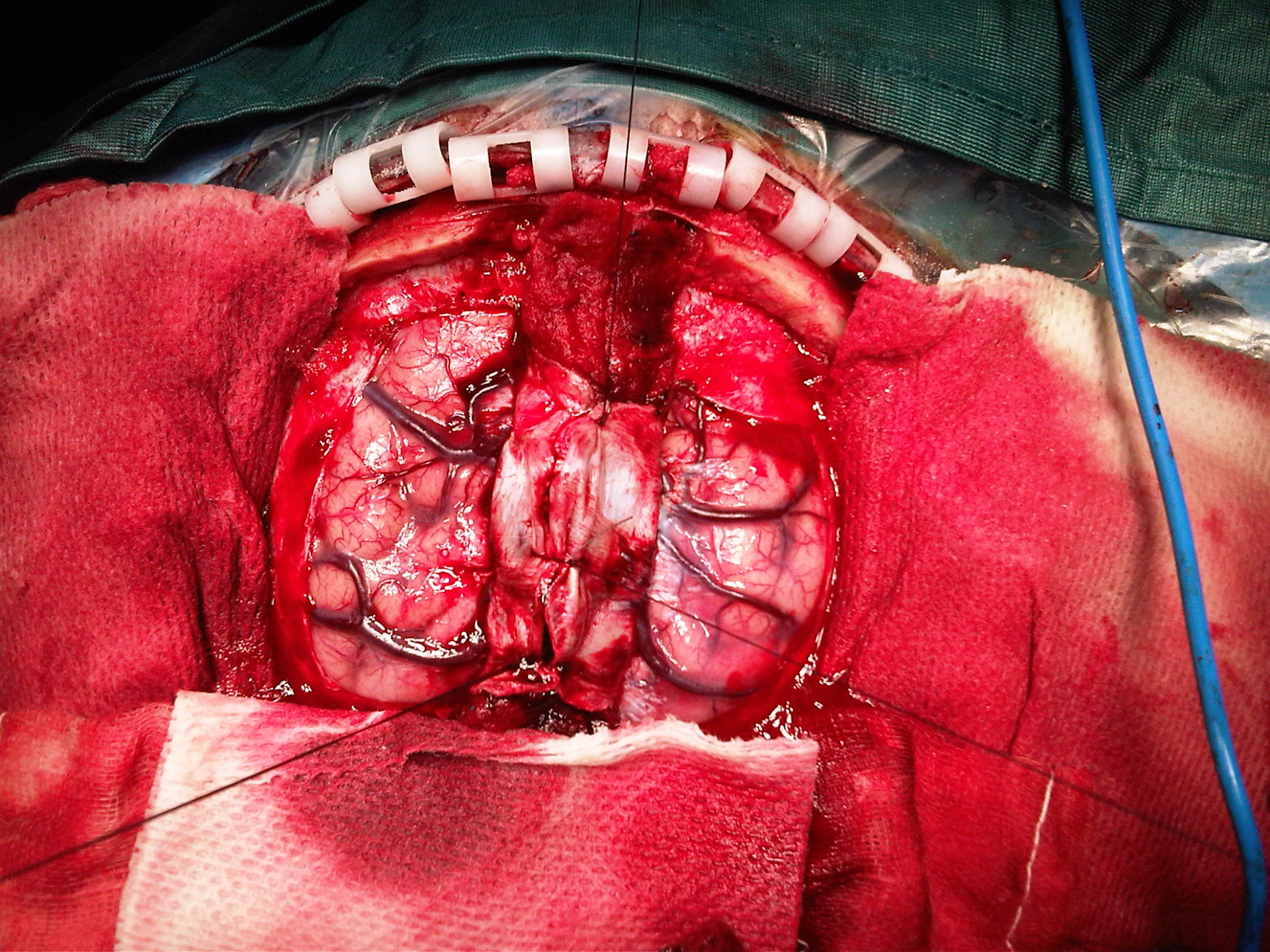

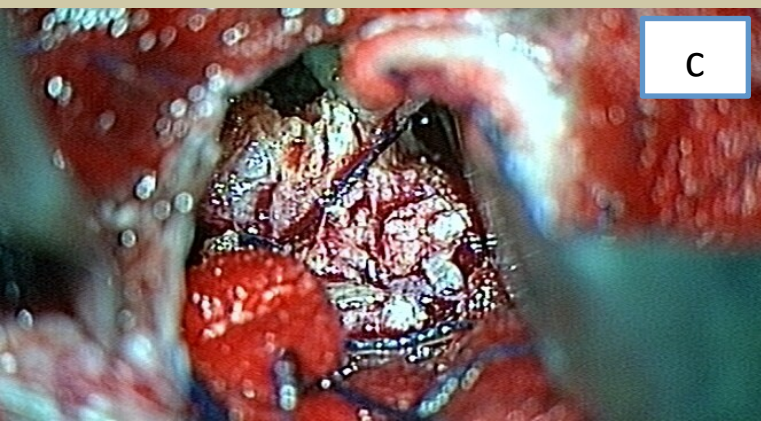
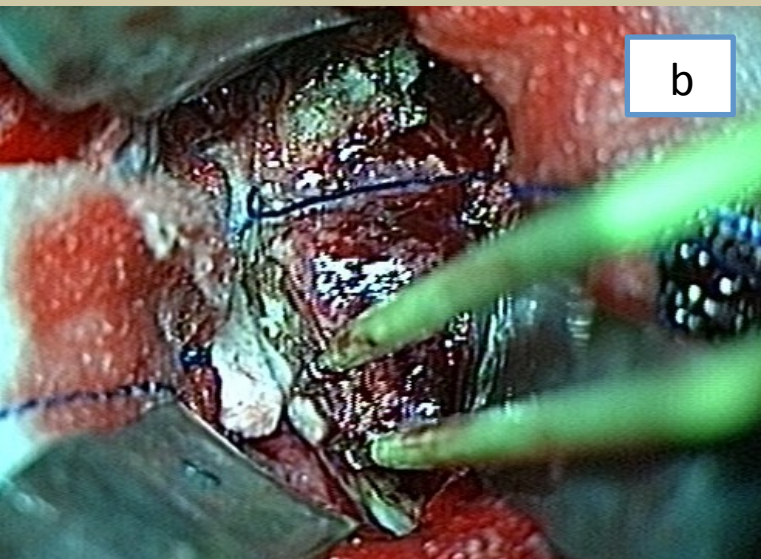
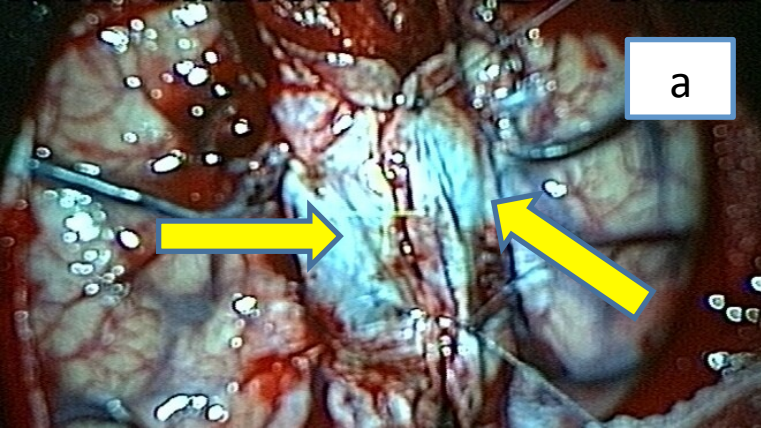
Lembo cutaneo



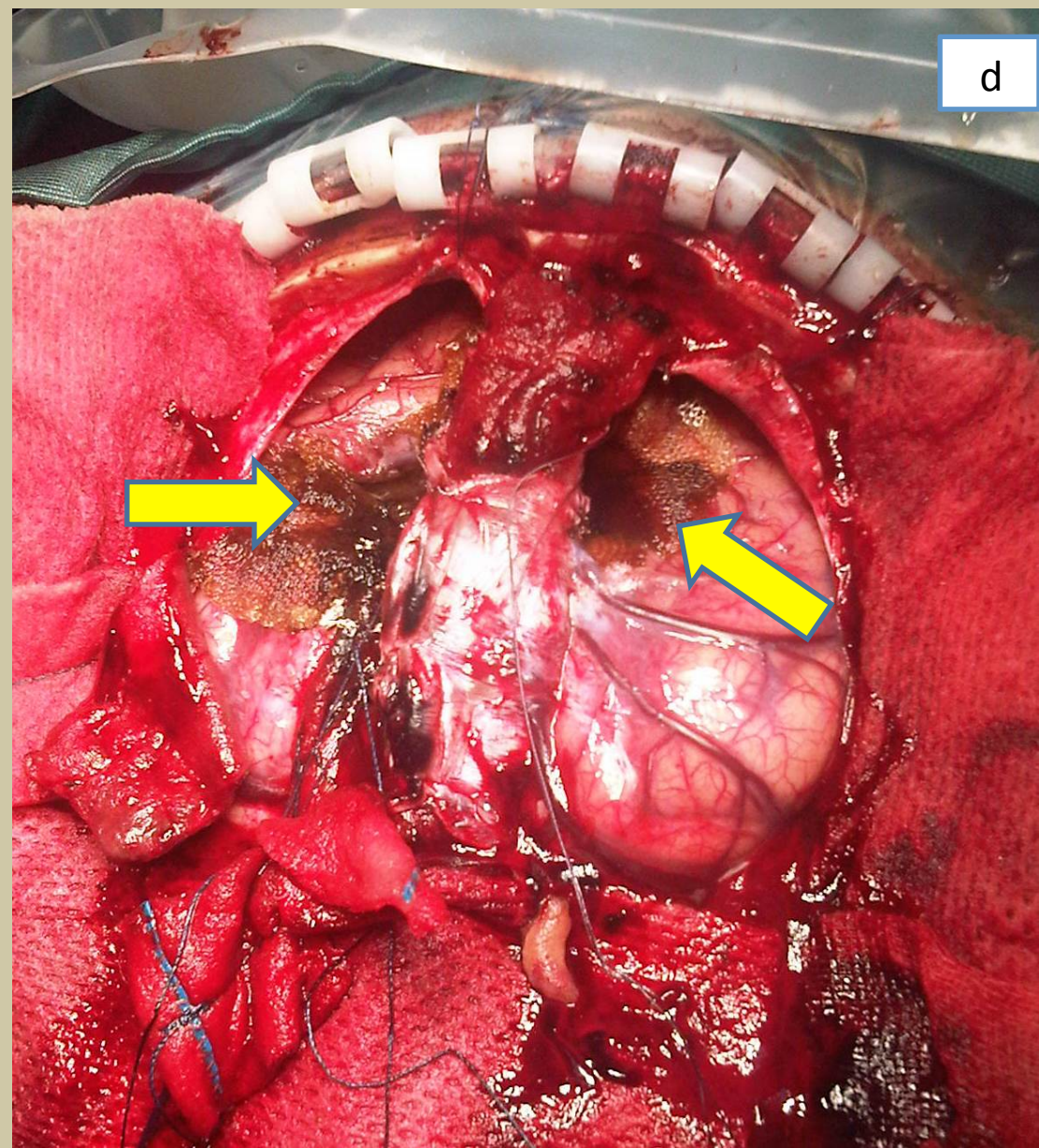
craniotomy







Asportazione del tumore. **a.** I due emisferi cerebrali con i due lembi di dura madre riuniti sul seno sagittale (frecche). **b e c.** esposizione del tumore a sinistra e a destra. **d.** Le cavità residue dopo l'exeresi tumorale (frecche)



Dopo la chiusura e la sospensione della dura madre viene ricostruito il lembo osseo con placche e viti in titanio (a) e sempre con lo stesso materiale l'osso viene fissato al cranio (b). Infine viene suturata la cute (c).

